



# Fecal specimen diagnosis 2019 novel coronavirus–infected pneumonia

JingCheng Zhang | SaiBin Wang | YaDong Xue

Department of Respiration, Jinhua Municipal Central Hospital, Jinhua Hospital of Zhejiang University, Jinhua, China

## Correspondence

JingCheng Zhang, Department of Respiration, Jinhua Municipal Central Hospital, Jinhua Hospital of Zhejiang University, 321000 Jinhua, China.

Email: [zjc1983@126.com](mailto:zjc1983@126.com)

## Abstract

The emergence and spread of 2019 novel coronavirus–infected pneumonia (COVID-19) from Wuhan, China, it has spread globally. We extracted the data on 14 patients with laboratory-confirmed COVID-19 from Jinhua Municipal Central hospital through 27 January 2020. We found that compared to pharyngeal swab specimens, nucleic acid detection of COVID-19 in fecal specimens was equally accurate. And we found that patients with a positive stool test did not experience gastrointestinal symptoms and had nothing to do with the severity of the lung infection. These results may help to understand the clinical diagnosis and the changes in clinical parameters of COVID-19.

## KEYWORDS

coronavirus, dissemination, nervous system, pathogenesis, virus classification

## 1 | INTRODUCTION

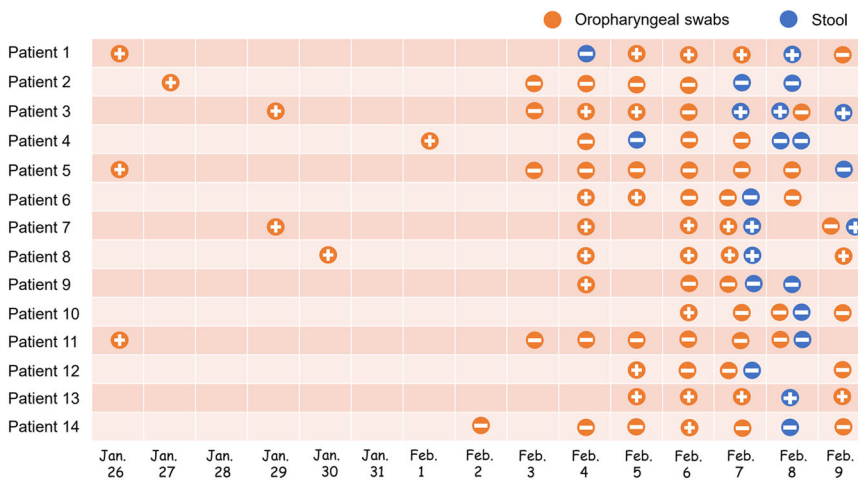
In December 2019, a new coronavirus (COVID-19) pneumonia outbreak occurred in Wuhan, China.<sup>1</sup> Since the virus was detected in December 2019, more than 77 000 people have been infected in China, causing more than 2600 deaths.<sup>2</sup> Globally, cases have been reported in 33 countries and five continents.<sup>3</sup> Patients' clinical manifestations included fever, cough, dyspnea, myalgia, fatigue, and chest computed tomography were ground-glass opacity.<sup>4</sup> A novel coronavirus currently named 2019 novel COVID-19, real-time reverse-transcriptase polymerase-chain-reaction (RT-PCR) method can be used for the detection of COVID-19 in oral swabs.<sup>5</sup> In SARS-CoV and MERS-CoV infected patients, intestinal infections are very common.<sup>6,7</sup> Results have now confirmed the presence of the live virus in stool samples from patients with COVID-19,<sup>8</sup> which means that stool samples may contaminate hands, food, and water, and may cause infection by invading the mouth, respiratory mucosa, and conjunctiva. We report the detection method of 14 cases with confirmed COVID-19 infection admitted to hospitals in Jinhua, aiming to investigate the other possible transmission route of this virus.

## 2 | METHODS

We performed a retrospective analysis of 14 laboratory-confirmed cases with COVID-19 pneumonia. Data were obtained from the Department of Infectious Diseases Jinhua Hospital of Zhejiang University. Patients were hospitalized from 27 January 2020 to 10 February 2020, with final follow-up for this report on 9 February 2020. Early we are confirmed cases with COVID-19 pneumonia were a RT-PCR assay for pharyngeal swab specimens, and that all oropharyngeal swabs specimens were collected by a senior infectious physician with more than 10 years of experience. Starting from 4 February 2020, we have added stool samples to all cases.

## 3 | RESULTS

The median age of the patients was 41 years (18–87 years), and 7 (50%) were female. The most common symptoms include fever (92.8%) and cough (71.4%), no fever is an 87-year-old female patient, all patients had no vomiting and diarrhea. Four patients (28.5%)



**FIGURE 1** Viral nucleic acid test results in 14 patients with COVID-19. COVID-19, coronavirus

returned from Wuhan, the remaining 10 (71.4%) had a history of contact with COVID-19 pneumonia patients.

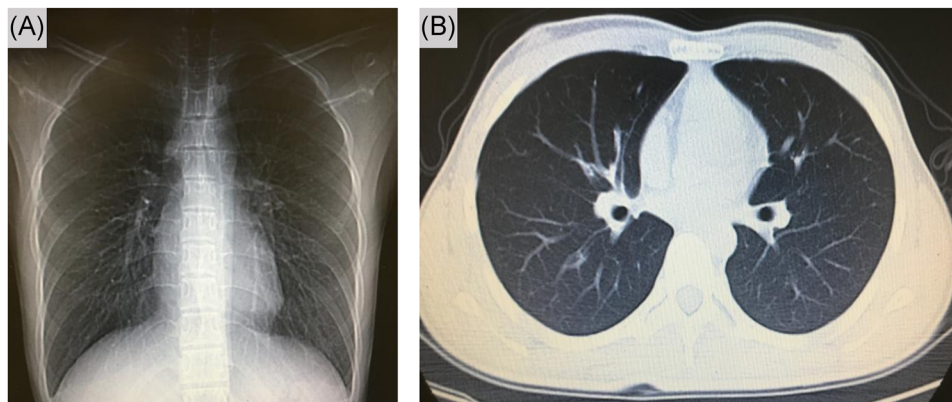
Since 4 February, we have collected patient samples intensively as the supply of PCR kits has increased. It was found that five of the 14 confirmed patients (35.7%) had a positive stool sample COVID-19 nucleic acid, and patients with positive stool samples were also positive for oropharyngeal swabs specimens at least the day before (Figure 1); The same trend is that patients with negative stool samples are also negative for oropharyngeal swabs for at least the first 2 days (Figure 1). This may indicate that the accuracy of fecal specimen detection and oropharyngeal swabs is the same.

All 14 patients had computed tomography on admission, 92.8% manifested as pneumonia. One patient (patient 3) chest computed tomography images did not demonstrate any consolidation or scarring (Figure 2), however, this patient was positive for multiple stools and oropharyngeal swabs specimens (Figure 1). Among the remaining 13 patients, ground-glass opacity was observed in both lungs. Two patients (patient 6 and patient 14) severely yielded more prominent abnormalities on chest computed tomography than nonsevere cases (Figure 3), the nucleic acid test was negative for stool samples in these two patients, this indicates that fecal specimens are not related

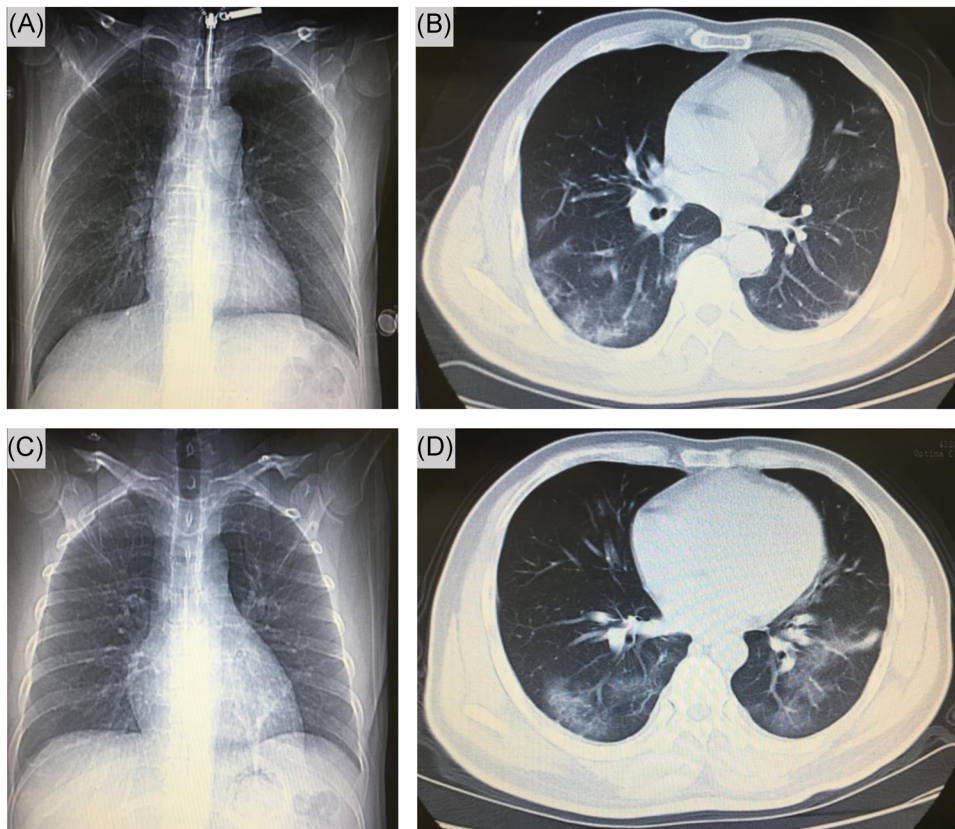
to nucleic acid positivity and severity. As of 9 February 2020, three patients recovered, but 11 were still being treated in the hospital.

#### 4 | DISCUSSION

According to the latest pilot experiment, four out of 62 stool specimens (6.5%) tested positive to COVID-19,<sup>9</sup> but we found very high accuracy in detecting nucleic acids in stool samples. Recently, reports of fecal nucleic acid tests to diagnose COVID-19 have increased.<sup>10,11</sup> In our cases, we found that patients with a positive stool test did not experience gastrointestinal symptoms and had nothing to do with the severity of the lung infection. Stool specimen collection will reduce medical staff infections compared to oropharyngeal swabs specimens, especially when protective equipment in China is inadequate. We are not sure if there is a fecal-oral transmission, but fomite transmission might have contributed considerably to the rapid spread of COVID-19. Finally, this report highlights the need for health protection, which should be considered for transmission through stool, these discoveries will curb the rapid spread of COVID-19 worldwide.



**FIGURE 2** Chest computed tomographic images, 5 February 2020 (illness day 10, hospital day 6)



**FIGURE 3** Chest computed tomographic images. Shown patient are chest images obtained at on day 5 (A, B) and another patient day 5 (C, D) after admission

#### ACKNOWLEDGMENT

The author thanks Dr. Saibin Wang for sharing her personal observations.

#### CONFLICT OF INTERESTS

The authors declare that there are no conflict of interests.

#### ORCID

JingCheng Zhang  <http://orcid.org/0000-0002-7555-8848>

#### REFERENCES

- Zhu N, Zhang D, Wang W, et al. A novel coronavirus from patients with pneumonia in China. *N Engl J Med*. 2020;382:727-733.
- National Health Commission of the People's Republic of China. <http://www.nhc.gov.cn/xcs/yqfkdt/202002/945bd98a9d884aeeb54d76afa02ca813.shtml>. Accessed on 25 February 2020.
- World Health Organization. Novel coronavirus(2019-nCoV): situation report-36. [https://www.who.int/docs/default-source/coronaviruse/situation-reports/20200225-sitrep-36-covid-19.pdf?sfvrsn=2791b4e0\\_2](https://www.who.int/docs/default-source/coronaviruse/situation-reports/20200225-sitrep-36-covid-19.pdf?sfvrsn=2791b4e0_2). Accessed 25 February 2020.
- Wang D, Hu B, Hu C, et al. Clinical characteristics of 138 hospitalized patients with 2019 novel coronavirus-infected pneumonia in Wuhan, China. *JAMA*. 2020. <https://doi.org/10.1001/jama.2020.1585>
- Zhou P, Yang XL, Wang XG, et al. Discovery of a novel coronavirus associated with the recent pneumonia outbreak in humans and its potential bat origin. *Nature*. 2020. <https://doi.org/10.1038/s41586-020-2012-7>
- Shi X, Gong E, Gao D, et al. Severe acute respiratory syndrome associated coronavirus is detected in intestinal tissues of fatal cases. *Am J Gastroenterol*. 2005;100(1):169-176.
- Ding Y, He L, Zhang Q, et al. Organ distribution of severe acute respiratory syndrome (SARS) associated coronavirus (SARS-CoV) in SARS patients: implications for pathogenesis and virus transmission pathways. *J Pathol*. 2004;203(2):622-630.
- Zhang Y, Chen H, Zhu S, et al. Isolation of 2019-nCoV from a stool specimen of a laboratory-confirmed case of the coronavirus disease 2019 (COVID-19). *China CDC Weekly*. 2020;2(8):123-124.
- Guan W, Ni Z, Hu Y, et al. Clinical characteristics of 2019 novel coronavirus infection in China. *N Engl J Med*. 2020. <https://doi.org/10.1056/NEJMoa2002032>
- Zhang H, Kang Z, Gong H, et al. The digestive system is a potential route of 2019-nCoV infection: a bioinformatics analysis based on single-cell transcriptomes. 2020. Preprint at <https://www.biorxiv.org/content/10.1101/2020.01.30.927806v1>
- Zhang W, Du RH, Li B, et al. Molecular and serological investigation of 2019-nCoV infected patients: implication of multiple shedding routes. *Emerging Microbes Infect*. 2020;9:386-389.

**How to cite this article:** Zhang J, Wang S, Xue Y. Fecal specimen diagnosis 2019 novel coronavirus-infected pneumonia. *J Med Virol*. 2020;1-3. <https://doi.org/10.1002/jmv.25742>